



## Case study: Mare with cancer

### Description

**Client Name: Dr med. vet. Ferdinand Denzinger**

**“Over the course of the treatment the sarcoids which had not been operated on turned black and fell off.”**

Some 5 years ago I treated a 10-year-old mare, a hopeless case, with her foal at her side. She had a tumour the size of a child’s head on her nostrils which had grown over the course of several years. Whenever the animal ate, this tumour bled so that its stall was covered in blood and looked like an abattoir. There were also five other smaller sarcoids spread over its body. The owner intended to have the mare put down once the foal was weaned.

I treated her as follows. I first surgically removed the large tumour on her nose. I had to cut into the tumour tissue as otherwise I would have had to remove her whole nose and the front part of her muzzle.

I used small pieces of tumour in the BICOM® therapy. Since bioresonance therapy works with the body’s or substance’s natural frequency patterns, I placed tumour tissue in what is known as the input cup (see diagram). This input cup is connected to the BICOM® device by cables which allows information from this tumour tissue to be fed into the device. The information from the tissue was inverted (shifted in mirror image) with a pre-installed program and fed back to the horse in amplified form as therapy oscillations via an output applicator.

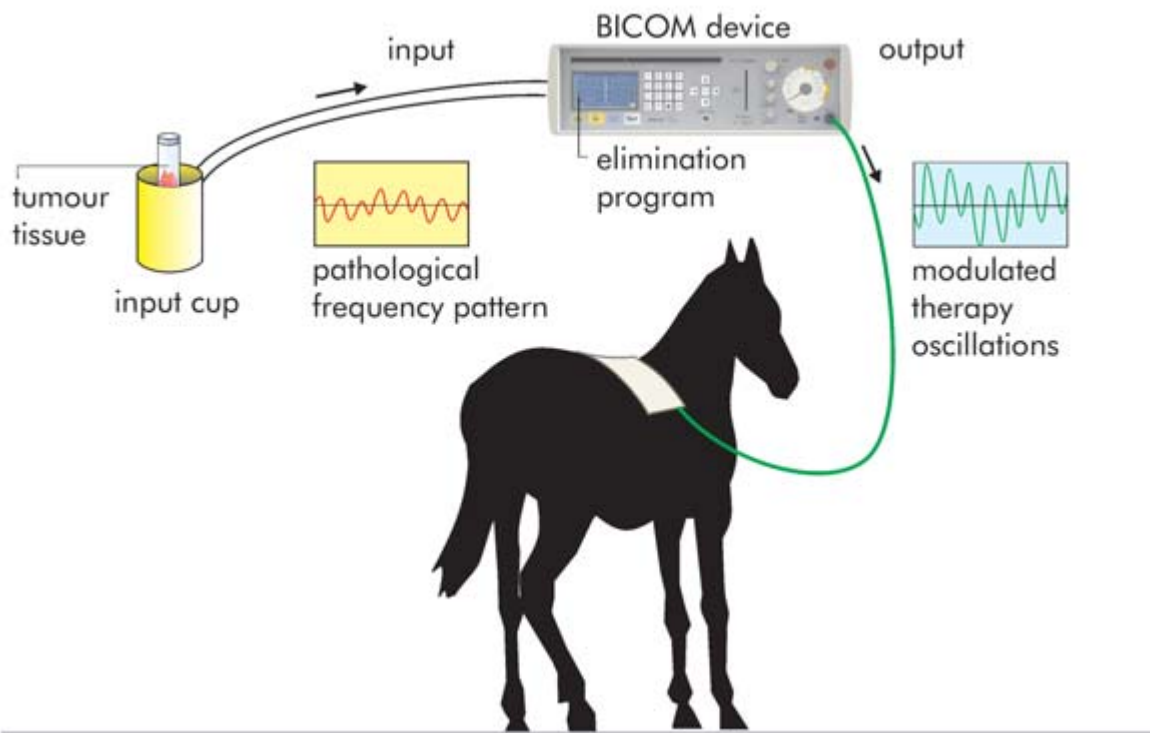
Several other programs stored in the BICOM® device, such as “toxin elimination” and “lymph activation,” for example, were also used.

A total of eight BICOM® treatment sessions were needed. The first two sessions took place on two consecutive days. I then treated the animal weekly and later just once a month.

Over the course of the treatment the sarcoids which had not been operated on turned black and fell off. The wound from the operated tumour also healed well. It took about six months for everything to heal fully!

This mare is still alive and has produced a healthy foal each year. The owner is extremely grateful as this is a valuable breeding mare. He is naturally enthusiastic and has had other horses treated since then. He has also told other breeders what happened and they have also consulted me as a result.

I urge all colleagues to have the courage to try new avenues. BICOM® treatment carries no risk. I have had nothing but positive experience. Think of the success you could achieve. So have faith!



Treatment strategy for eliminating harmful influences

## Category

1. Veterinary

## Date Created

2017/12/08

## Author

davidfranklin